

## CASE REPORT

## Severe Pneumonia Treated Successfully with Levofloxacin and Oseltamivir During Flu Epidemic

Pınar Akın Kabalak<sup>1</sup>, Asım Esenkaya<sup>2</sup><sup>1</sup>Clinic of Chest Diseases, Düzce Atatürk State Hospital, Düzce, Turkey<sup>2</sup>Clinic of Radiology, Düzce Atatürk State Hospital, Düzce, Turkey

## Abstract

Viral pneumonia is an important cause of community acquired pneumonias (CAP). It's not only specific to childhood period. Although immunocompromised adults are susceptible; all young and healthy adults are at risk. Viral pneumonias are usually underestimated due to lack of diagnostic modalities so a clinician must be aware of. Co-infection of viruses and bacteria is not uncommon and can be mortal especially in a flu epidemic, therefore, in the absence of diagnostic tools initiating to anti-viral treatment without delay is important.

**KEYWORDS:** Bronchopneumonia, epidemiology, oseltamivir**Received:** 01.05.2015**Accepted:** 03.08.2015

### INTRODUCTION

CAP could be mortal especially in elder patients with co morbidities. It is diagnosed in adults approximately 5.16 to 6.11 cases per 1000 persons per year [1]. According to World Health Organization (WHO) data, 450 million pneumonia cases occur per year and have %7 mortality incidence increasing by age [2]. Although lower airways are sterile, lungs are infected by aspiration of microorganisms that colonize in upper airways. Development of pneumonia depends on host defence, existence of chronic diseases, age and virulence of microorganism [3].

Bacteria, viruses, fungi and parasites are all responsible pathogens for pneumonia. Viral pneumonia accounts for 13-50% of single pathogen diagnosed CAP cases and 8-27% of mixed bacterial-viral pneumonia [4].

Diagnostic methods for viral pneumonia are limited and are not used widely thus clinical differences from bacterial pneumonia must be considered. Constitutional symptoms and atypical radiological involvement are common clues. Non-productive cough, fever, myalgia, headache are main symptoms developing slowly. In the influenza period, viruses should be remembered in the first rank as a causative agent of pneumonia. Delay to start anti-viral treatment can cause respiratory failure.

Influenza virus, respiratory syncytial virus, adenovirus, parainfluenza virus, coronavirus, rhinovirus are main viral pathogens for community-acquired viral pneumonia. Influenza type A is usually the most virulent pathogen and responsible for epidemics by antigenic drift [5]. Diagnostic methods for viruses are various such as viral culture, cytological evaluation, rapid antigen detection and gene amplification. However these are not always available.

We report two cases of severe pneumonia without any immunosuppressive medical condition treated with levofloxacin and oseltamivir in an epidemic period.

### CASE PRESENTATION

#### Case 1

A 42-years-old man without any medical history admitted to our hospital with severe fatigue, myalgia, and headache. Nearly ten days ago he had admitted to his family physician with non-productive cough and fever. Aminopenicillins-clavulanic acid and ibuprofen-pseudoephedrine were prescribed. At the third day of this treatment complaints of abdominal pain, anorexia and headache were also added.

#### Case 2

A 42 years woman was admitted to emergency department with shortness of breath and cough. She had symptoms for about five days. She had used ibuprofen-pseudoephedrine and vitamin C tablets without a prescription. About ten days



**Address for Correspondence:** Pınar Akın Kabalak, Düzce Atatürk Devlet Hastanesi, Göğüs Hastalıkları Kliniği, Düzce, Türkiye E-mail: pinarakinn@yahoo.com  
©Copyright 2016 by Turkish Thoracic Society - Available online at www.toraks.dergisi.org

ago she was complaining for upper respiratory tract infection symptoms. There was no hospital admission or antibiotic use. She had myalgia and anorexia also.

Both patients were not using any regular medication for any of chronic disease.

Their clinical and demographic features were summarized in Table 1. As shown in Table 2 infection parameters were high before treatment and were in normal ranges after treatment. Case 1 had mild thrombocytopenia without bleeding.

Patients' sputum culture, microscopy and blood culture were unremarkable. Sputum was negative for Acid resistant bacillus (ARB) and mycobacterium tuberculosis complex wasn't detected in culture.

In case 1 chest radiograph revealed bilateral heterogeneous infiltration from top to lower zone of lung (Figure 1A) and in case 2 infiltrations had lower zone predominance (Figure 2A). Because of clinical deterioration and admission during flu pandemic period computed thorax tomography (CTT) was performed. CTT revealed multiple patchy consolidations accompanied by ground glass areas. Pleural effusion wasn't observed (Figures 1B,1C,2B,2C).

## RESULT

In accordance with all these data both patients had severe pneumonia. Due to being in a flu epidemic period and existence of patchy ground glass opacities on CTT we couldn't exclude viral agents. For certain diagnosis technical facilities of laboratory like polymerase chain reaction (PCR) or antigen detection tests were insufficient in our hospital.

Patients' had clinical deterioration and decrease in oxygen saturation so antiviral treatment was began without delay. They took oral 75 mg oseltamivir twice a day for ten days. Due to possibility of bacterial superinfection levofloxacin 750 mg was administered once daily for 2 weeks together with antiviral therapy. Nasal oxygen, intravenous hydration, bronchodilator and antipyretics were added as supportive treatments. On the tenth day of treatment patients' general condition was better and vital signs were normal. Within 72 hours fever response was achieved in both cases. Oxygen saturation was above 95% without oxygen inhalation, there were no need to bronchodilators and arterial blood pressure was in normal ranges without intravenous fluid replacement. After treatment inflammatory markers were within normal limits (Table 2). On the chest X-ray and CTT performed after treatment completely regression was seen consistent with patients' clinical status (Figures 1D, 1E, 1F, 2D, 2E, 2F).

## DISCUSSION

Although pneumonia is treated as outpatients more often by using some scores like CURB-65 (confusion, urea, respiratory rate, blood pressure and age of 65) or PSI (pneumonia severity index) clinicians can decide to hospitalize the patient [6]. However patient's general medical condition is always important. Thus although our patients didn't have comorbidities and pneumonia scores were low they were needed to be treated in hospital. Because supplementary therapies like oxygen, intravenous hydration or bronchodilators must be added to antibiotics in viral pneumonias.

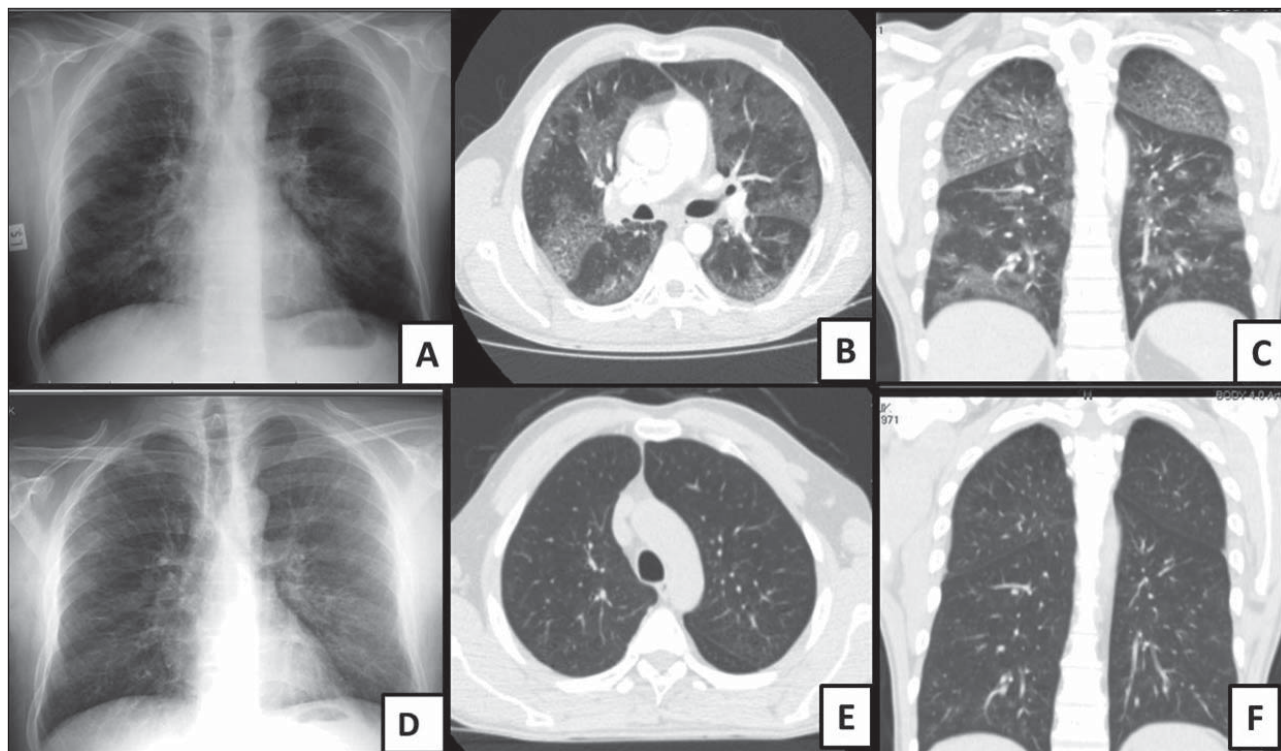
**Table 1.** Clinical and demographic features of patients

	Case 1	Case 2
Age/Gender	41/male	42/female
Smoking status	Smoker	Non smoker
Fever	37.8°C	37.7°C
Pulse rate	90-110/min	100-120/min
Transcutaneous oxygen	%91	%88
Chest auscultation	Bibasilar fine crackles	Bibasilar fine crackles + ronchi
Blood pressure	90/60	Normal
Sputum/Blood culture	No pathogen	No pathogen
Sputum acid-fast bacilli	Negative	Negative

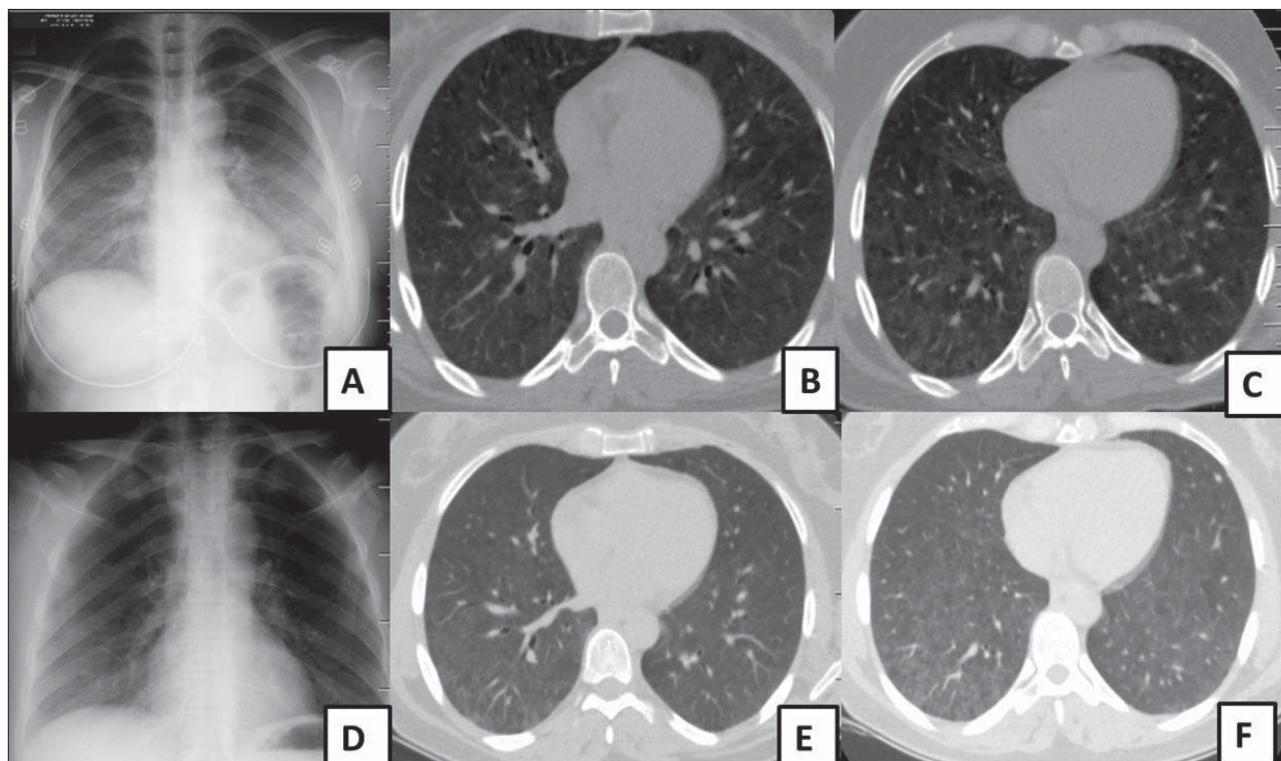
**Table 2.** Comparison of laboratory values of patients before and after treatment

Laboratory	Case 1		Case 2	
	Pre-treatment	Post treatment	Pre-treatment	Post treatment
White blood cells	17.37/L	9.58/L	18.11/L	11.93/L
Neutrophil	15.04/L	5.51/L	14.55/L	8.63/L
Lymphocyte	7.0/L	3.27/L	13.6/L	2.6/L
CRP	32.08 mg/dL	2.5 mg/dL	10.6 mg/dL	0.75 mg/dL
Sedimentation	105 mm/hour	32 mm/hour	73 mm/hour	8 mm/hour
Albumine	3.4 g/dL	4.1 g/dL	3.8 g/dL	4.2 g/dL
LDH	491 U/L	223 U/L	317 U/L	211 U/L
Platelets	92/L	385/L	457/L	369/L

CRP: C- reactive protein, LDH: Lactate dehydrogenase.



**Figure 1.** (A) Bilateral heterogeneous infiltration on chest X-ray. (B, C) Multiple patchy consolidations accompanied by ground glass areas without pleural effusion on computed thorax tomography (Case 1). (D, E, F): Completely regression on chest X-ray and computed thorax tomography (Case 1).



**Figure 2.** (A) Bilateral infiltration showing lower zone predominance on chest X-ray. (B,C) Multiple patchy consolidations accompanied by ground glass areas (Case 2). (D, E, F) Completely regression on chest X-ray and computed thorax tomography (Case 2).

Viruses like influenza virus, respiratory syncytial virus, adenovirus, parainfluenza virus, coronavirus, rhinovirus constitutes %13-50 of CAP and usually occur with bacterial agents so to diagnosis purely viral pneumonia is difficult.

Influenza type A and B are responsible for most of viral pneumonias especially in epidemic. It can change its' glycoprotein structure (neuraminidase and hemagglutinin) by antigenic shift and drift so that increase virulence [4,7]. To

distinguish, clinical clues and epidemiology can help the physician to consider viral agents. Constitutional symptoms are very significant. Fever, myalgia and gastrointestinal symptoms are more obvious in influenza than other viral pathogens [7]. Our patients had fever; myalgia and case one had gastrointestinal symptoms. Also our patients' inflammatory markers were high supporting to bacterial co-infection so empiric antibiotics were added to oseltamivir treatment.

Respiratory viruses damage upper airway epithelium and reach lung parenchyma by secretions or haematogenous [8]. Influenza, adenovirus and herpes group have cytopathic effects on respiratory epithelium. Influenza virus causes necrotizing bronchitis and/or bronchiolitis, inflammatory cell infiltration in alveoli and diffuse alveolar damage in severe cases. Although patchy bilateral alveolar infiltrations and interstitial involvement are common radiological findings parenchymal attenuation disturbances, nodules, micro nodules, interlobular septal thickening can be seen on CTT [9]. There were bilateral ground glass opacities and patchy infiltrates both of patients. These radiological findings can be related malignant/non-malignant reasons so they are non-specific. Broncho alveolar carcinoma is first differential diagnosis as malignancy. Our patients' symptoms were so acute and responded to therapy in ten days unlike malignancy. Hypersensitivity pneumonia and desquamative interstitial pneumonia could be considered. For these nodular opacities are expected with ground glass areas. Patients didn't have nodules on CTT also there was no risk factor or antigen exposure. If they had haemoptysis diffuse alveolar haemorrhage can be conceivable. Actually viral pneumonia which is clinically serious can cause alveolar haemorrhage. There weren't decline in haemoglobin or haemoptysis [10]. They didn't have medical history suggesting vasculitis or immunological disease. So systemic steroid wasn't added to therapy. If patients had any immunocompromised condition aspergillus could be remembered.

H5N1 and H7N9 are avian influenza and H1N1 is swine influenza responsible for pandemics and outbreaks in winter season. In June 2009, the WHO raised its pandemic alert level to the highest level because of outbreak of H1N1 influenza A virus infection [11]. In late March and April 2013, human cases of novel avian influenza A H7N9 infection in China were reported and a rise in the number of cases occurred in late 2013 and early 2014 in influenza season [12]. Both patients administered our hospital in November 2013 so influenza was susceptible.

In an epidemic period if patient is highly suspected clinically and radiologically oseltamivir should be initiated in 48 hours to prevent viral replication. 75 mg twice a day for five days is standard therapy. In severe cases or presence of clinical progression to prolong to ten days or 150 mg twice a day is applicable [13,14]. Both of our patients had administered to hospital with delay and their clinical condition wasn't good so oseltamivir were given 75 mg twice a day for 10 days. So benefit of supplementary therapies shouldn't be denied.

## CONCLUSION

Viral pneumonias should be remembered as a differential diagnosis when bilateral and patchy ground glass opacities were detected on CTT and if patients' clinical status is suggestive for viral causes; physician should not hesitate to start antiviral agents immediately.

**Author Contributions:** Concept - P.A.K.; Desing - P.A.K.; Supervision - P.A.K.; Fundings - P.A.K., A.E.; Materials - P.A.K.; Data Collection and/or Processing - A.E.; Analysis and/or Interpretation - P.A.K.; Literature Review - A.E.; Writer - A.E., P.A.K.; Critical Review - P.A.K.

**Conflict of Interest:** No conflict of interest was declared by the authors.

**Financial Disclosure:** The authors declared that this study has received no financial support.

## REFERENCES

1. Marrie TJ, Huang JQ. Epidemiology of community-acquired pneumonia in Edmonton, Alberta. An emergency department-based study. *Can Respir J* 2005;12:139. [\[CrossRef\]](#)
2. Ruuskanen O, Lahti E, Jennings LC, Murdoch DR. Viral pneumonia. *Lancet* 2011;377:1264-75. [\[CrossRef\]](#)
3. Wunderink RG, Waterer GW. Community-acquired pneumonia: pathophysiology and host factors with focus on possible new approaches to management of lower respiratory tract infections. *Infect Dis Clin North Am* 2004;18:743. [\[CrossRef\]](#)
4. Jennings LC, Anderson TP, Beynon KA, et al. Incidence and characteristics of viral community-acquired pneumonia in adults. *Thorax* 2008;63:42-8. [\[CrossRef\]](#)
5. Mosenifar Z, Jeng A, Kamangar N, et al. Viral pneumonia. <http://emedicine.medscape.com/article/300455-clinical>.
6. Ananda-Rajah MR, Charles PG, Melvani S, et al. Comparing the pneumonia severity index with CURB-65 in patients admitted with community acquired pneumonia. *Scand J Infect Dis* 2008;40:293-300. [\[CrossRef\]](#)
7. Walsh EE, Cox C, Falsey AR. Clinical features of influenza A virus infection in elderly hospitalized persons. *J Am Geriatr Soc* 2002;50:1498-503. [\[CrossRef\]](#)
8. Levy MM, Baylor MS, Bernard GR, et al. Clinical issues and research in respiratory failure from severe acute respiratory syndrome. *Am J Respir Crit Care Med* 2005;171:518-26. [\[CrossRef\]](#)
9. Tomás Franquet Imaging of Pulmonary Viral Pneumonia, DOI: <http://dx.doi.org/10.1148/raidol.11092149>. [\[CrossRef\]](#)
10. Engeler CE, Tashjian JH, Trenkner SW, et al. Ground-Glass opacity of the lung parenchyma: a guide to analysis with high-resolution CT. *AJR* 1993;160:249-51. [\[CrossRef\]](#)
11. Fineberg HV. Pandemic preparedness and response-lessons from the H1N1 influenza of 2009. *N Engl J Med* 2014;370:1335-42. [\[CrossRef\]](#)
12. World Health Organization. WHO Risk Assessment. Human infections with avian influenza A(H7N9) virus. [http://www.who.int/influenza/human\\_animal\\_interface/RiskAssessment\\_H7N9\\_21Jan14](http://www.who.int/influenza/human_animal_interface/RiskAssessment_H7N9_21Jan14) [\[CrossRef\]](#)
13. WHO. Clinical management of human infection with avian influenza A (H5N1) virus [http://www.who.int/influenza/resources/documents/clinical\\_management\\_h5n1\\_15\\_08\\_2007/en/index.html](http://www.who.int/influenza/resources/documents/clinical_management_h5n1_15_08_2007/en/index.html)
14. Falsey AR, Walsh EE. Viral pneumonia in older adults. *Clin Infect Dis* 2006;42:518-24. [\[CrossRef\]](#)